

## BRANCHIAL ARCH ANOMALIES OF NECK: A CASE SERIES

Received : 12/04/2023  
 Received in revised form : 18/05/2023  
 Accepted : 31/05/2023

**Keywords:**  
 Branchial arch Anomalies, Congenital, Neck

Corresponding Author:  
**Dr. Shilpa Jha,**  
 Email: drshilpa2014@gmail.com

DOI: 10.47009/jamp.2023.5.3.327

Source of Support: Nil,  
 Conflict of Interest: None declared

*Int J Acad Med Pharm*  
 2023; 5 (3); 1628-1632



**Paromita Patra<sup>1</sup>, Gunveen Kaur<sup>2</sup>, Apurvdeep Kaur<sup>2</sup>, Shilpa Jha<sup>3</sup>, Sandeep Kumar Jha<sup>4</sup>**

<sup>1</sup>Associate Professor, Department of ORLHNS, Mata Gujri Memorial Medical College and LSK Hospital, Kishanganj

<sup>2</sup>Junior Resident, Department of ORLHNS, Mata Gujri Memorial Medical College and LSK Hospital, Kishanganj

<sup>3</sup>Associate Professor, Department of Pathology, Mata Gujri Memorial Medical College and LSK Hospital, Kishanganj

<sup>4</sup>Professor, Department of ORLHNS, Mata Gujri Memorial Medical College and LSK Hospital, Kishanganj

### Abstract

**Background:** Anomalies of the branchial arch are third most common cause of mass in the neck. They can present as cysts, sinuses, or fistulae. Second branchial arch anomalies are the most common followed by first, third and fourth branchial arch anomaly. The aim of this study is to strengthen clinicians' understanding of branchial arch anomalies and reduce risk of clinically missed diagnosed cases using a uniform technique based on embryologic principles. **Materials and Methods:** We are presenting a series of 8 cases of branchial arch anomalies that presented to our outpatient department within last two years. 6 out of 8 cases presented with complaint of openings in the neck since birth with occasional history of discharge and 2/8 cases presented with swelling in the lateral aspect of neck. They underwent fistulography, Computed Tomography Scan and Magnetic Resonance Imaging in some cases to define the type and extent of the fistula and type of cyst. **Result:** Out of the 8 cases 3 had internal opening in oral cavity (second arch anomaly), 1 had communication with Stensen's duct (first arch anomaly), 2 were opening internally into pyriform fossa (fourth arch anomaly), 1 cyst was seen abutting the tragal cartilage (first arch anomaly) and 1 cyst seen abutting carotid artery (second arch anomaly). **Conclusion:** Radiological investigations are essential to delineate the entire tract to enable complete surgical excision so as to avoid recurrences.

## INTRODUCTION

Branchial anomalies are congenital anomalies arising from the first to fourth pharyngeal arches. The most common type of branchial apparatus anomaly is branchial cyst arising from the second cleft (40-95%). Anomalies arising from 1st (5-25%), 3rd (2-8%) and 4th cleft (1%) are rarer.<sup>[1]</sup> Since they are congenital anomalies, they present in childhood, though, they may not be obvious or symptomatic until later.

Branchial anomalies may present as cysts, sinuses or fistulae.<sup>[2]</sup>

Complete branchial cleft fistulae are rare. Incomplete fistulae are more common, although, they may not be symptomatic. Complete fistulae usually present as a discharging defect along the anterior border of SCM. The internal course and opening depends on the cleft that it is derived from. In 2<sup>nd</sup> cleft anomaly the tract runs deep to the platysma, opens into the tonsillar fossa.<sup>[2]</sup>

1<sup>st</sup> cleft anomaly are distributed in the lateral neck below the external auditory canal (EAC), above the hyoid bone, anterior to the sternocleidomastoid muscle, and posterior to the submandibular angle.<sup>[3]</sup> In 3rd and 4th cleft anomaly the internal opening is found in the pyriform fossa base and apex respectively.<sup>[3]</sup> We are presenting our experience in the management of 8 cases of branchial anomalies, over a two year period in our tertiary academic institution, with emphasis on pre-op evaluation of the fistulae and cysts so that there complete extent and tract is identified which would in turn enable complete surgical excision.

## MATERIALS AND METHODS

This study includes 8 cases of branchial anomalies (comprising of 6 complete branchial fistulae and 2 branchial cysts), which presented to the Department of Otolaryngology, Head and Neck Surgery, Mata

**Table 1: Types of Anomalies**

S.No	Age/Sex	Anomaly	Special Investigation	Treatment
1.	12/F	1 <sup>st</sup> Branchial arch fistula	Fistulogram/ CT Fistulogram Neck	Excision of tract with Partial Parotidectomy
2.	29/F	1 <sup>st</sup> Branchial arch cyst	USG neck / FNAC/ CECT neck	Excision
3.	5/M	2 <sup>nd</sup> Br. arch fistula	Fistulogram	Excision
4.	13/F	2 <sup>nd</sup> Br. arch fistula	Fistulogram/ CT neck	Excision
5.	20/F	2 <sup>nd</sup> Br. arch fistula	Fistulogram	Excision of tract
6.	15/M	2 <sup>nd</sup> Br. arch cyst	USG neck / FNAC/ CECT neck	Excision
7.	16/F	4 <sup>th</sup> Br. arch fistula	USG neck/ CEMRI neck	Excision of tract
8.	17/M	4 <sup>th</sup> Br. arch fistula	Fistulogram	Excision

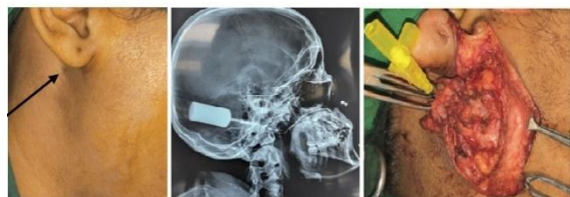**Table 2: Incidence of Individual Anomalies.**

Branchial arch Involved	Cyst		Fistulae		Total	
	No.	%	No.	%	No.	%
1st branchial arch Work I Work II	1	12.5	1	12.5	2	25
2nd branchial arch	1	12.5	3	50	4	50
3rd branchial arch	-	-	-	-	-	-
4th branchial arch	-	-	2	12.5	2	25

## CASE SERIES

### CASE 1

A 12-year-old female patient presented with an opening in the right side of neck just below the right ear lobule. X ray fistulogram showed a tract communicating with the Stensen's duct. Patient underwent complete surgical excision of the tract with partial parotidectomy. Post op period and follow up was uneventful [Figure 1].



**Figure 1:** 1<sup>st</sup> branchial arch anomaly with a fistulous opening in the right side just below the right ear lobule (marked by arrow). X ray fistulogram shows the tract communication with the Stensen's duct and draining into the oral cavity. Intraoperatively, the tract was delineated with the aid of an intravenous canula. It was excised in toto along with partial parotid tissue.

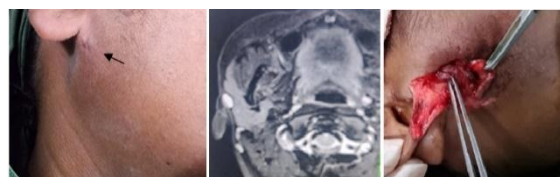
### CASE 2

A 29-year-old female, presented with a cystic swelling below the lobule of right pinna from past 8 months. CT scan of the neck was suggestive of 1st branchial cleft cyst. Intraoperatively the cyst was found to abutting the tragal cartilage [Figure 2]. Complete excision of cyst was performed. Post operative period was uneventful with no signs of recurrence on follow up. Histopathological examination of the specimen was in favor of branchial cyst.

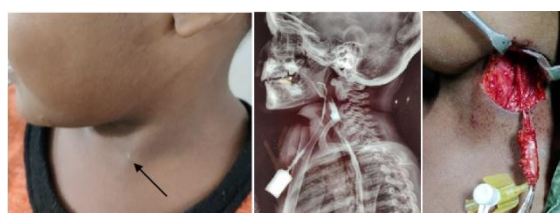### CASE 3

A 5-year-old male presented with opening in the left side of neck anterior to the anterior border of SCM with complaint of intermittent discharge since birth.

X ray fistulogram showed a complete tract extending up to the right tonsillar fossa. Patient underwent complete surgical excision of the tract. On post operative follow up, patient was healthy and there were no signs of recurrence. Histopathological examination of the specimen was suggestive of fistulous tract. [Figure 3]



**Figure 2:** 1<sup>st</sup> branchial arch anomaly presented with a cystic swelling below the lobule of right pinna (Marked by arrow). MRI T2 weighted image showed a cystic swelling at the level right superficial parotid gland. Intraoperatively, the cyst was found abutting the tragal cartilage and was excised in toto.

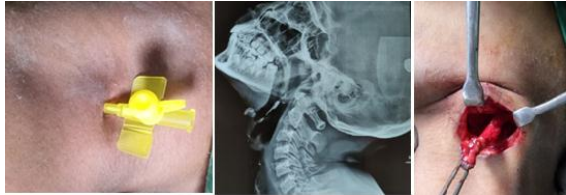

**Figure 3:** 2<sup>nd</sup> branchial arch anomaly presented as an opening of the tract on the left side of neck at the level of anterior border of SCM (marked by arrow). X ray fistulogram revealed 2<sup>nd</sup> branchial arch anomaly with a fistulous tract extending up to the left tonsillar fossa. Fistulous tract was delineated with the aid of an intravenous canula and was excised completely.

### CASE 4

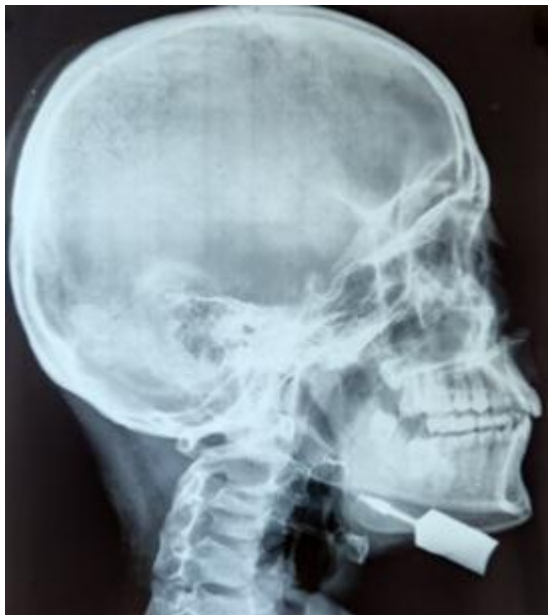A 13-year-old female, presented with opening in the left side of neck, with history of intermittent discharge. X ray fistulogram showed a complete tract extending up to the tonsillar fossa. Complete surgical excision of the tract was done [Figure 4] However, patient came back 2 months later with collection under the scar mark. On examination, pus

was seen coming out from the floor of left EAC. Patient was managed with systemic antibiotics followed by CT fistulogram which showed stained tract leading up to the left EAC. Patient underwent second surgical excision where the tract along with cuff of surrounding tissue was excised along with previous surgical scar tissue. Post operative period was uneventful and histopathological examination of the specimen was suggestive of fistulous tract.



**Figure 4:** 2<sup>nd</sup> brachial arch anomaly with fistulous opening in the left side of neck. X-ray fistulogram showed a complete tract extending up to the left tonsillar fossa. The tract was identified and removed in toto.

Case 5: A 20-year-old female presented with a fistulous opening present in right side of neck at the level of angle of mandible. X ray fistulogram showed tract extending up to the right tonsillar fossa [Figure 5].

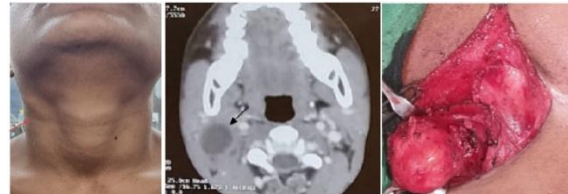

**Figure 5:** X ray fistulogram showing 2<sup>nd</sup> arch anomaly tract extending from a fistulous opening present in right side of neck at the level of angle of mandible up to the right tonsillar fossa.

Complete surgical excision of the tract was done. Post operative period was uneventful and no signs of recurrence were observed in subsequent follow ups. Histopathological examination of the specimen was suggestive of fistulous tract.

### CASE 6

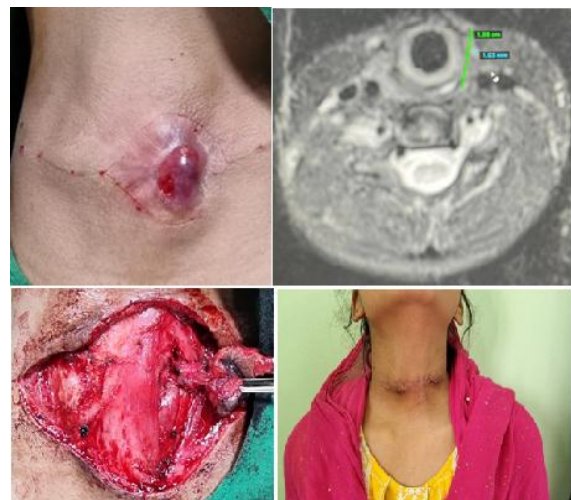A 15-year-old male presented with a cystic swelling in the right side of neck at the level of hyoid bone. CT scan of the neck was suggestive of 2<sup>nd</sup> brachial arch cyst type II (Fig 6). Patient underwent complete surgical excision with removal of cyst in toto. Histopathological examination of the specimen was in favor of branchial cyst.



**Figure 6:** 2<sup>nd</sup> arch anomaly presented with a cystic swelling in the right side of neck at the level of hyoid bone (marked by arrow). CECT Neck showing a cystic swelling (marked by arrow) abutting the carotid sheath. The cyst was excised in toto.

### CASE 7

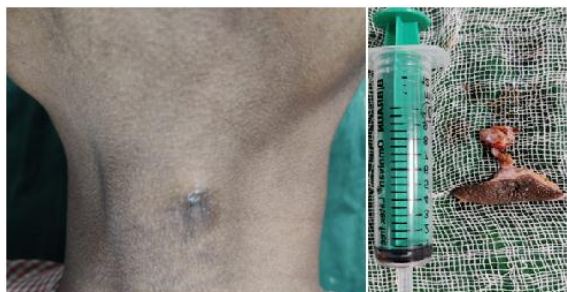A 16-year-old female presented with history of intermittent mucopurulent discharge from right side neck, from past 8 years. Patient had undergone incision and drainage twice elsewhere. On examination, a fistulous opening along with inflamed scarred tissue was present in left side of neck just anterior to anterior border of SCM. CEMRI Neck showed left sided 4<sup>th</sup> branchial cleft fistula. Complete surgical excision of fistulous tract along with the scarred tissue was done. (Fig 7) Post operative period was uneventful.



**Figure 7:** 4<sup>th</sup> branchial arch anomaly presenting with fistulous opening along with inflamed scarred tissue in left side of neck just anterior to anterior border of SCM. A T2 hyperintense thin tract is noted arising from loculated collection around the superior border of left lobe of thyroid gland opening into left pyriform sinus. Intraoperatively, the fistulous tract was seen entering the pyriform fossa just behind the posterior border of thyroid cartilage (marked by arrow).

### CASE 8

A 17-year-old male presented with a history of discharging fistula point in the left side of neck with scar tissue around it due to previous incision and drainage done elsewhere. X ray fistulogram showed collection of dye in the left pyriform sinus. Surgical excision of the tract along with the scar tissue was done. [Figure 8]



**Figure 8: 4<sup>th</sup> branchial cleft anomaly presenting as external opening of the tract on the left side of neck at the extending up to the left pyriform sinus. Fistulous tract was excised completely.**

### DISCUSSION

The branchial arches develop between the fourth and seventh week of gestation and form the embryological precursors of the face, neck and pharynx.<sup>[3]</sup> In total, six pairs of branchial arches form on either side of the pharyngeal foregut in cranio-caudal succession. The fifth pharyngeal arch is usually only rudimentary, or never forms, so ultimately only five arches contribute to adult anatomical structures. Schematically, the sixth arch is often represented as part of the fourth arch due to its small size.<sup>[3]</sup>

Von Baer described the branchial apparatus consists of three layers: the outer most layer lined by ectoderm called clefts and the inner most layer lined by endoderm called pouches, between them there is a mesodermal lining layer called arches.<sup>[4]</sup>

The first arch and cranial aspect of the second pharyngeal arch enlarge and thicken combining with the third and fourth pharyngeal arches to form an ectoderm-lined cavity called the cervical sinus of His (or cervical cyst).<sup>[5]</sup>

The incomplete involution of branchial apparatus during embryogenesis or aberrant development of these structures leads to branchial anomalies formation.

Depending on the anatomic location, branchial anomalies are classified into first, second, third, and fourth arch/cleft anomalies. Branchial anomalies are the second most common head and neck congenital lesions in children with thyroglossal duct remnants being the most common.<sup>[6]</sup> Branchial anomalies are most commonly seen in the first three decades of life. Sinuses are reported usually in the first decade while cysts usually reported in second and third decade of life.

In our study of 8 subjects, male: female ratio is 1:1.7 with female preponderance unlike other studies which show a male preponderance.<sup>[7,8]</sup> The range of the age was from 5 years to 29 years with mean age of 15.88 years.

Second branchial anomalies are considered to be the commonest with figures up to 95% being reported. The remainder of branchial anomalies is derived from first branchial remnants (1–8%) with third and fourth branchial anomalies being quite rare.<sup>[3]</sup>

First Branchial Arch Anomalies typically present as a sinus, cyst or fistula between the external auditory canal and submandibular area. Sinus will have an opening in the upper neck or in the floor of the external auditory canal, and a fistula will have an opening in both of these sites. Work in 1972 subdivided first branchial cleft anomalies into two groups, Type I and Type II.<sup>[9]</sup>

Type I anomalies are purely ectodermal in origin and present as cystic masses adjacent to the external auditory canal. They are duplications of the membranous external auditory canal and contain squamous epithelium but no skin adnexa or cartilage.

Type II anomalies may present as cysts, sinuses or fistulae in the region of the angle of the mandible. They are ectodermal and mesodermal in origin, hence they contain squamous epithelium, skin adnexa (hair follicles, sweat and sebaceous glands) and cartilage.

In our case series, 1 patient each was classified as Work Type I and Work Type II first branchial anomaly. 2 out of 8 cases (25%) were identified as first branchial apparatus anomalies.

**Second Branchial Cleft/Pouch Anomalies:** Second branchial cleft anomalies most commonly present as cysts followed by sinuses and fistulae. A persistent fistula of the second branchial cleft and pouch usually has its external opening in the neck near mid or lower part of SCM muscle and opens in to the oropharynx usually in the intra-tonsillar cleft of palatine tonsil whereas branchial cyst are present within the submandibular space.<sup>[2]</sup>

They have previously been classified into four different sub-types by Bailey in 1929.<sup>[10]</sup>

Type I – Most superficial and lies along the anterior surface of sternocleidomastoid deep to the platysma, but not in contact with the carotid sheath.

Type II – Most common type where the branchial cleft cyst lies anterior to the sternocleidomastoid muscle, posterior to the submandibular gland, adjacent and lateral to the carotid sheath.

Type III – Extends medially between the bifurcation of the internal and external carotid arteries, lateral to the pharyngeal wall.

Type IV- Lies deep to the carotid sheath within the pharyngeal mucosal space and opens into the pharynx.

Third and fourth branchial cleft anomalies mimic the second branchial cleft anomalies externally but have their internal opening in the pyriform sinuses internally. They are usually distinguished

anatomically by their relationship to superior laryngeal nerve. 3rd cleft anomalies are usually above it and 4th cleft presents below it. Further, most of the third branchial cleft cysts present in the posterior cervical space, posterior to the sternocleidomastoid muscle. 4th cleft anomalies arise from pyriform sinus apex, descend in trachea-oesophageal groove and often present as sinus tracts coursing from pyriform apex to left lobe of thyroid and may present as recurrent abscess or recurrent suppurative thyroiditis (Case 7, 8).<sup>[11,12]</sup>

Diagnosis is usually made by a proper history taking, clinical examination, imaging studies and histopathology. Radiological imaging enables a proper diagnosis and classification and therefore enables proper preoperative planning of surgical management.<sup>[13]</sup> For sinus presentation, CT sinogram is an apt radiology which delineates the tract completely and shows relation of the tract to great vessels. CT sinogram gives information regarding entire course of tract and also regarding inner opening in mucosal surface. Thus CT sinogram can differentiate between diagnosis of sinus and fistula. In our series, 6 cases underwent X-ray fistulogram and two cases underwent CT fistulogram.

In cases with cystic neck masses both CECT/MRI are suitable. MRI is superior in terms of delineating contents of cystic masses and relation with surrounding structures in neck.

In all patients, imaging, regardless of the modality, was essential in preoperative planning of the operative approach for definitive management.

Surgical excision is the definitive treatment for branchial anomalies, and the surgical plan needs to be tailored to each case. Cases with history of previous Incision & Drainage and presence of scarred tissue, should be excised completely along with the tract and cyst.

In our study 1/8 (12.5%) cases had recurrence of disease for which patient underwent re-exploration and removal of tract along with cuff of surrounding tissue. The reported recurrence rate can be as high as 14–22% after surgical excision when there is a history of prior infection or incomplete excision.

So, it is important to establish correct diagnosis with regard to type of branchial anomaly to achieve complete excision and prevent recurrence, this is important because recurrent cases are associated with surgery induced scarring and fibrosis which make complete re-excision very challenging.

## CONCLUSION

1. First branchial fistulae are often related to important glandular structures like Parotid gland, Submandibular gland so for complete removal of fistulae they might require partial or complete excision of the salivary glands.

2. Second branchial arch anomalies may pass through bifurcation of carotid arteries so CT fistulography / CECT Neck can give an early idea and surgeons need to be very careful during surgery for adequate excision without injuring the major vessels.
3. Third and fourth arch anomalies are relatively rarer. We saw two out of eight cases of fourth arch anomaly.
4. Although the study size is limited in our series, we did have majority cases related to second arch as has been noted in other studies. Further this study includes varied presentation of all the common branchial arch anomalies.
5. Radiological investigations (CT fistulogram/ X-Ray fistulogram) are important to delineate the entire extent of the tract and to know whether it is a sinus or a fistula.
6. Complete surgical excision is the only definitive treatment for branchial anomalies.

## REFERENCES

1. Coste AH, Lofgren DH, Shermetaro C. Branchial Cleft Cyst. [Updated 2022 Sep 12]. In: StatPearls [Internet]. Treasure Island (FL): StatPearls Publishing; 2023 Jan.
2. Mehmi N, Kumar R, Sagar P, Singh CA, Kumar R, Thakar A, Sharma SC. Importance and Impact of Appropriate Radiology in the Management of Branchial Cleft Anomalies. *Indian J Otolaryngol Head Neck Surg.* 2019 Oct;71(Suppl 1):953-959. doi: 10.1007/s12070-019-01634-w. Epub 2019 Mar 23. PMID: 31742101; PMCID: PMC6848690.
3. Adams A, Mankad K, Offiah C, Childs L. Branchial cleft anomalies: a pictorial review of embryological development and spectrum of imaging findings. *Insights Imaging.* 2016 Feb;7(1):69-76. doi: 10.1007/s13244-015-0454-5. Epub 2015 Dec 10. PMID: 26661849; PMCID: PMC4729717.
4. Frisdal A, Trainor PA. Development and evolution of the pharyngeal apparatus. *Wiley Interdiscip Rev Dev Biol.* 2014 Nov-Dec;3(6):403-18.
5. Mandell DL. Head and neck anomalies related to the branchial apparatus. *Otolaryngol Clin North Am.* 2000 Dec;33(6):1309-32.
6. Guarisco JL. Congenital head and neck masses in infants and children. Part II. *Ear Nose Throat J.* 1991 Feb;70(2):75-82. PMID: 2044478.
7. Prasad SC, Azeez A, Thada ND, Rao P, Bacciu A, Prasad KC. Branchial anomalies: diagnosis and management. *Int J Otolaryngol.* 2014;2014:237015. doi: 10.1155/2014/237015. Epub 2014 Mar 4. PMID: 24772172; PMCID: PMC3960728.
8. Bist SS, Purohit K, Agarwal V, Bharti B, Monga U. Complete Second Branchial Fistula: Diagnostic Imaging and Surgical Aspects. *Int J Otorhinolaryngol Clin.* 2016;8(1):6-10.
9. Triglia J, Nicollas R, Ducroz V, Koltai PJ, Garabedian E. First Branchial Cleft Anomalies: A Study of 39 Cases and a Review of the Literature. *Arch Otolaryngol Head Neck Surg.* 1998;124(3):291–295. doi:10.1001/archotol.124.3.291
10. Bailey H. Branchial cysts and other essays on surgical subjects in the facio-cervical region. London: Lewis & Company; 1929.
11. Liston SL. Fourth branchial fistula. *Otolaryngol Head Neck Surg.* (1981) 89:520–2. 10.1177/019459988108900402
12. Waldhausen JH. Branchial cleft and arch anomalies in children. *Semin Pediatr Surg.* 2006 May;15(2):64-9. doi: 10.1053/j.sempedsurg.2006.02.002. PMID: 16616308.
13. Harnsberger R et al (2011) Diagnostic imaging: head and neck, 2nd edn. Amirsys, Lippincott.